



BHARATHIDASAN
UNIVERSITY

Program: M.Sc., Biomedical Science

Course Title : Neurobiology

Cranial Nerves

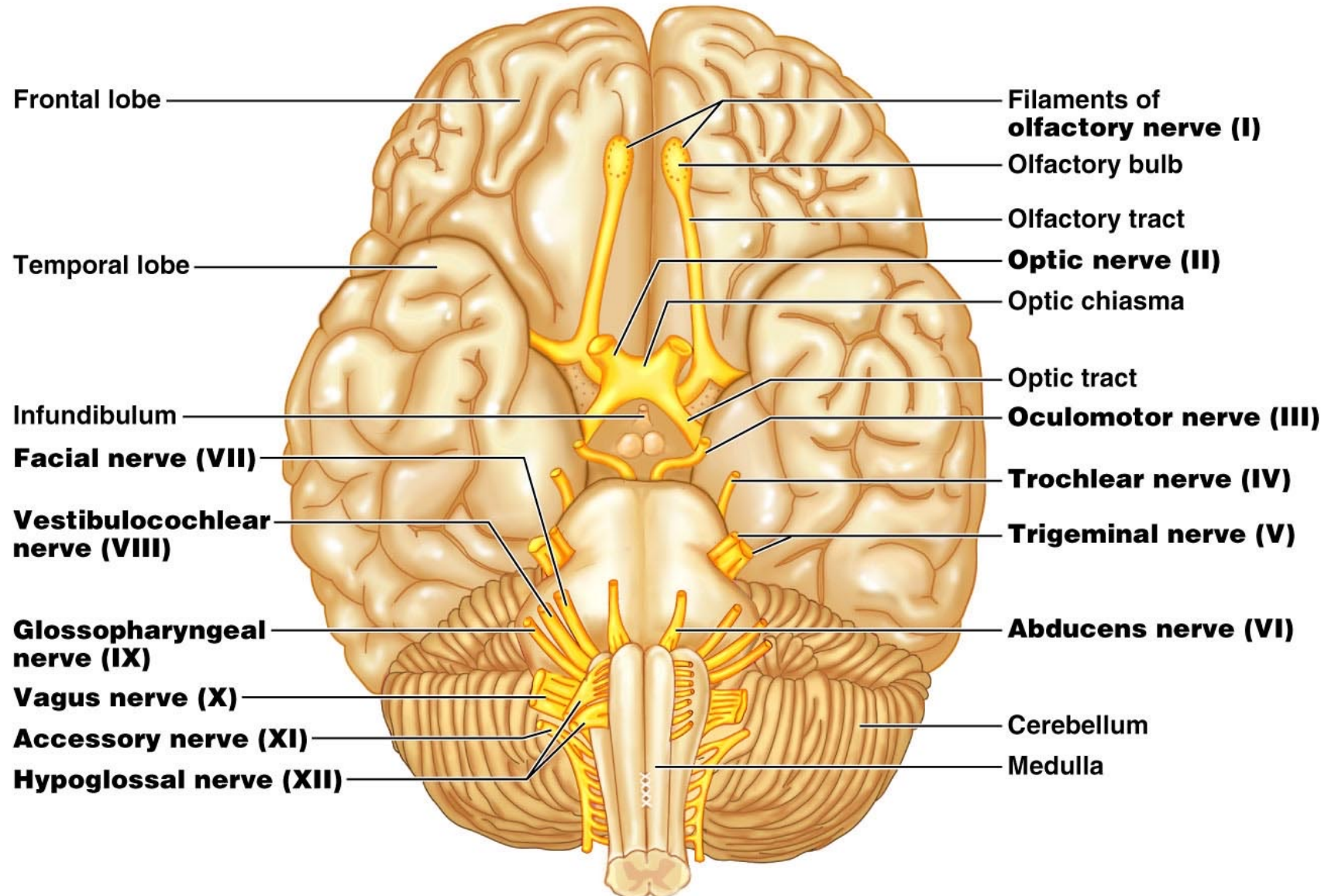
Prof. Narkunaraja Shanmugam

Dept. of Biomedical Science

Cranial Nerves

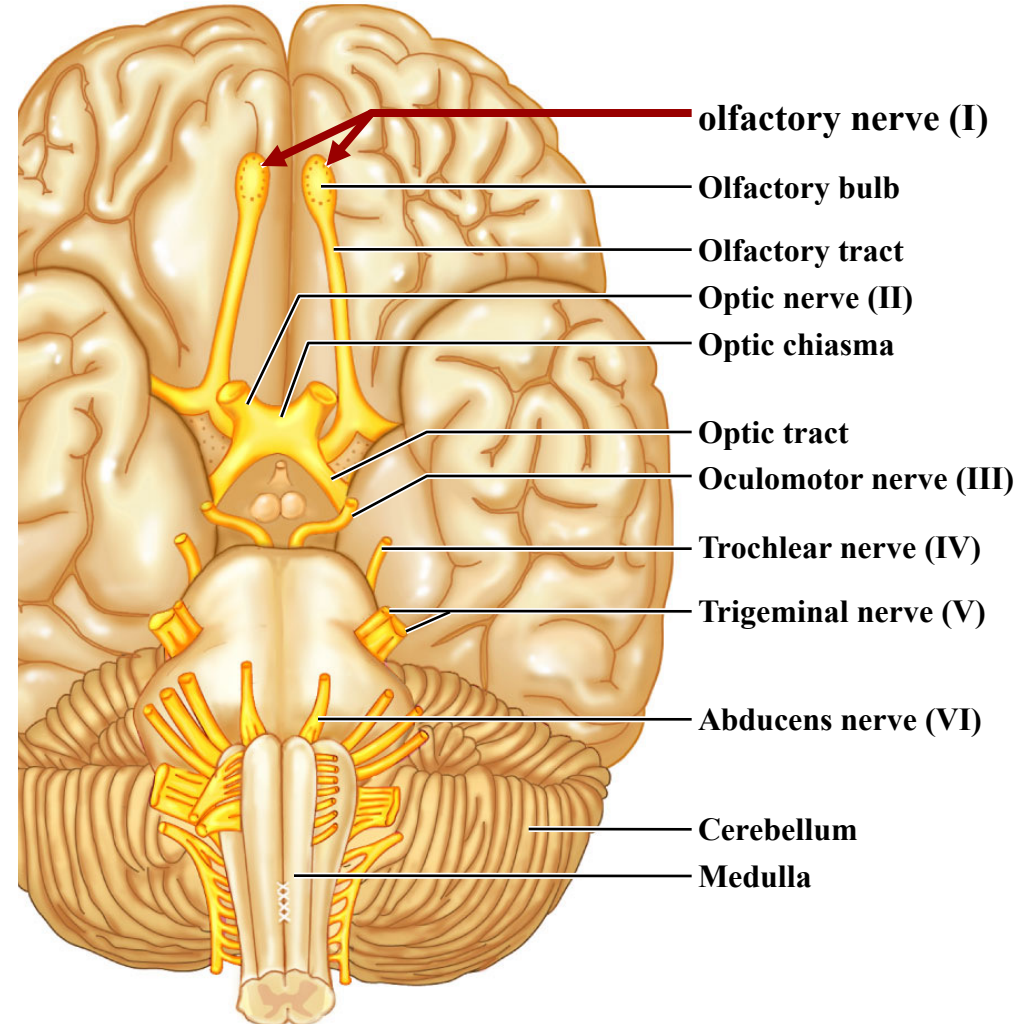
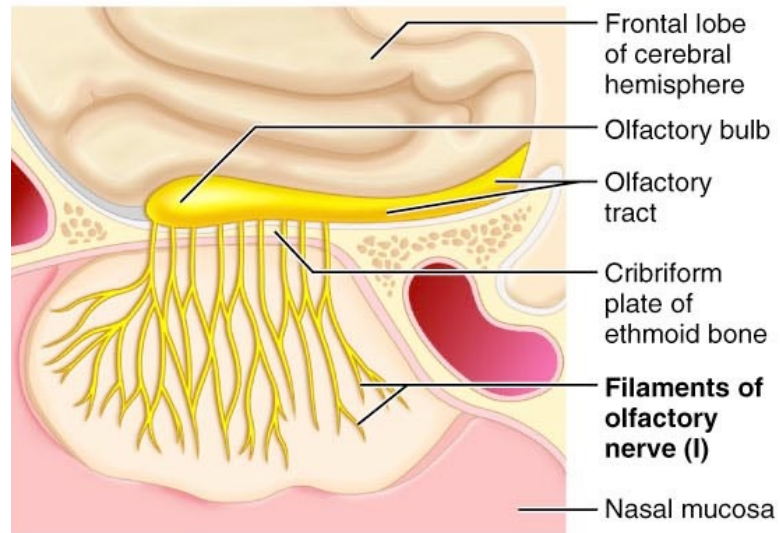
- Attach to the brain and pass through foramina of the skull
- Numbered from I–XII
- Cranial nerves I and II attach to the forebrain
 - All others attach to the brain stem
- Primarily serve head and neck structures
 - The vagus nerve (X) extends into the abdomen

The 12 Pairs of Cranial Nerves



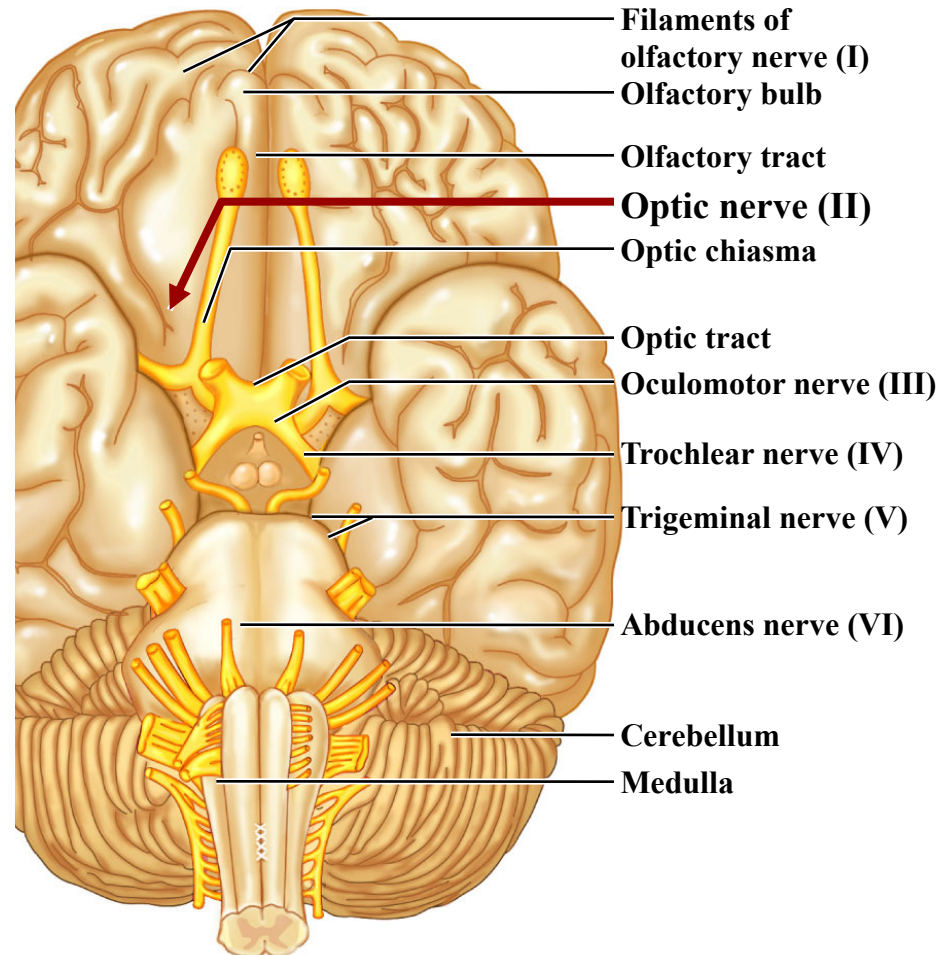
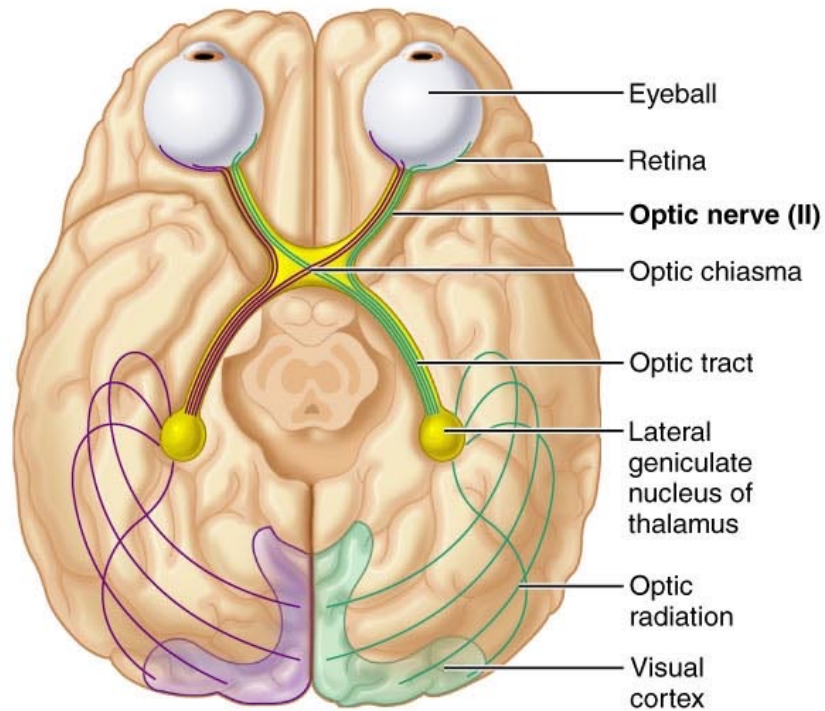
Olfactory Nerves (I)

- Sensory nerves of smell



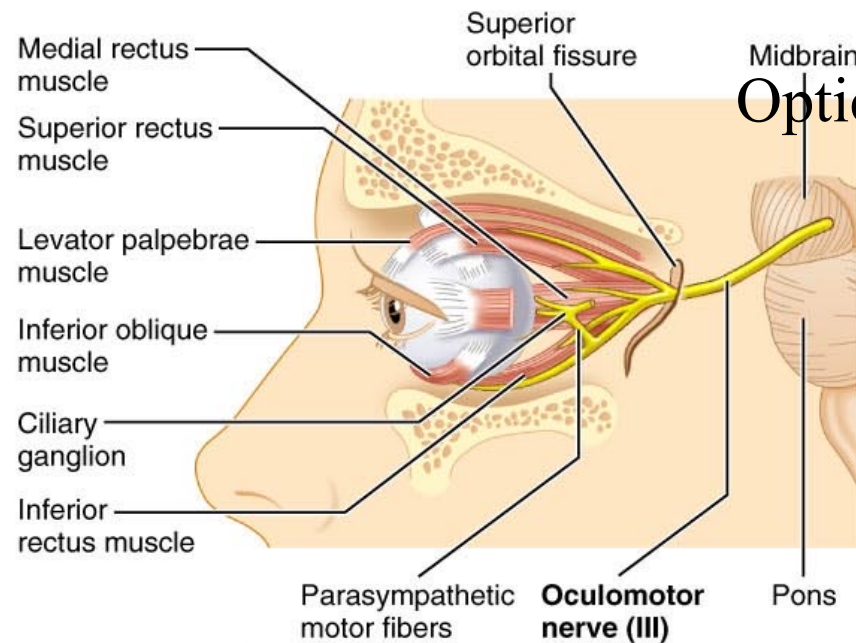
Optic Nerve (II)

- Sensory nerve of vision

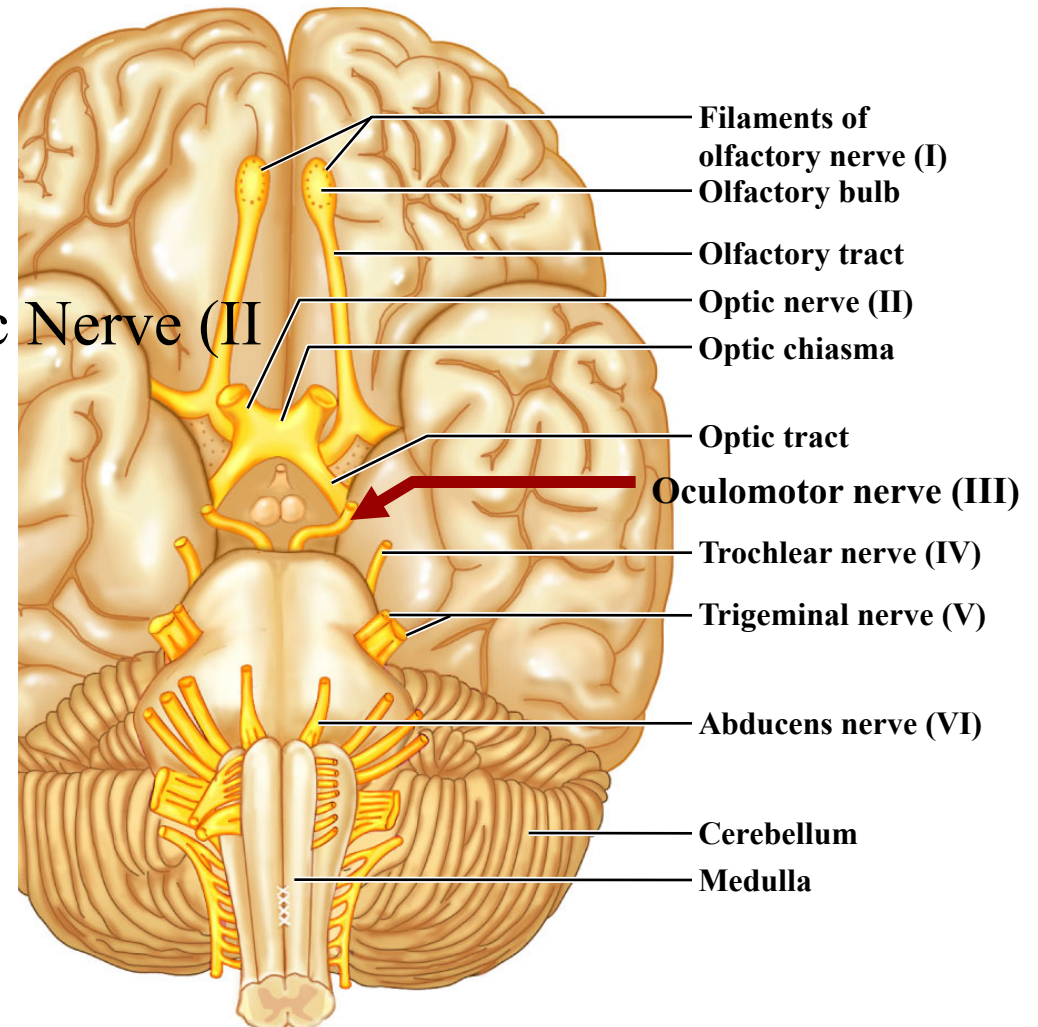


Oculomotor Nerve (III)

- Innervates four of the extrinsic eye muscles

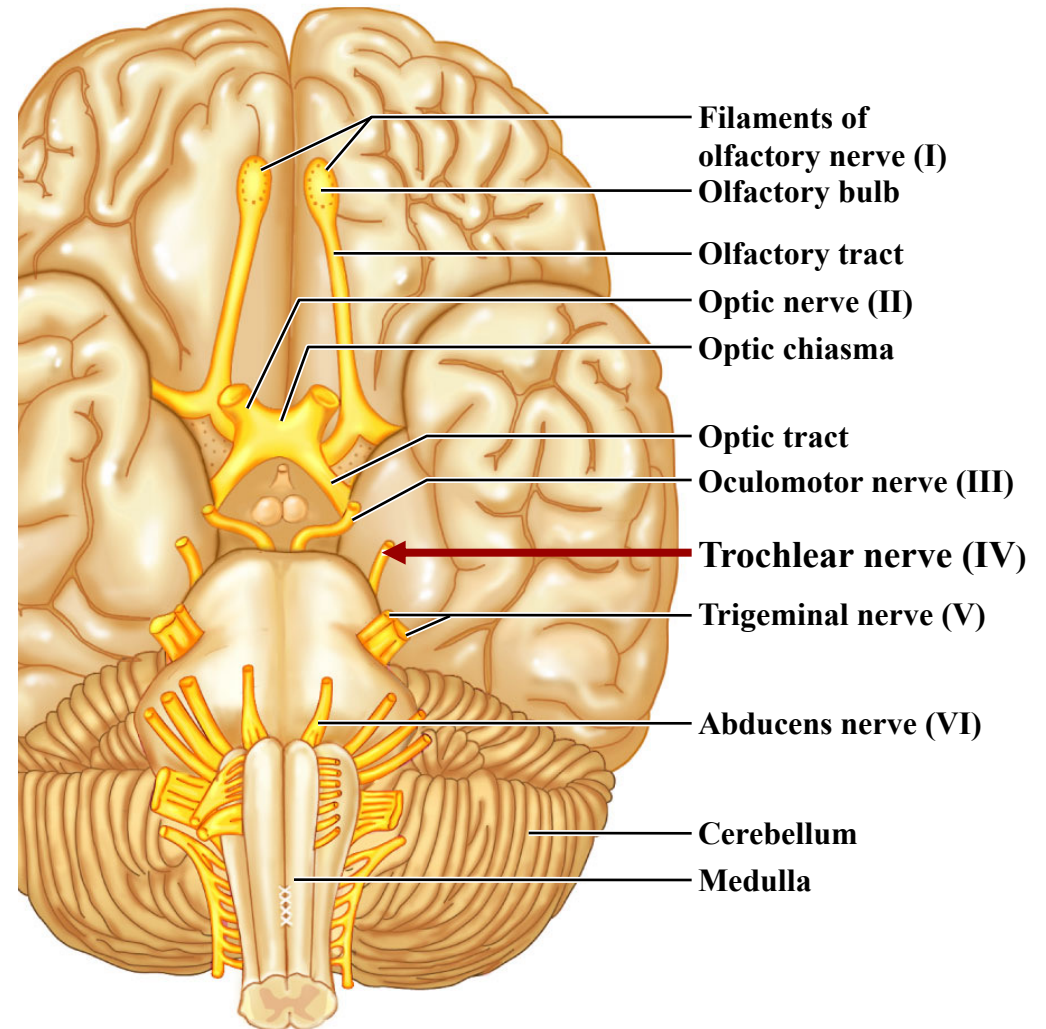
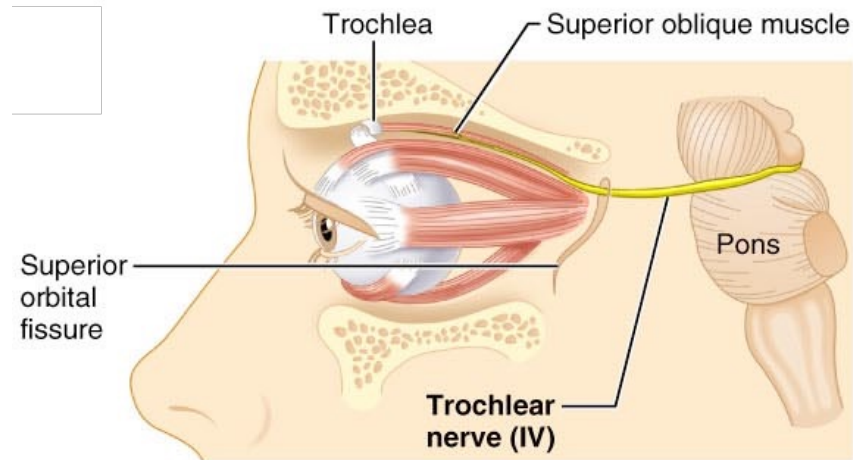


Optic Nerve (II)



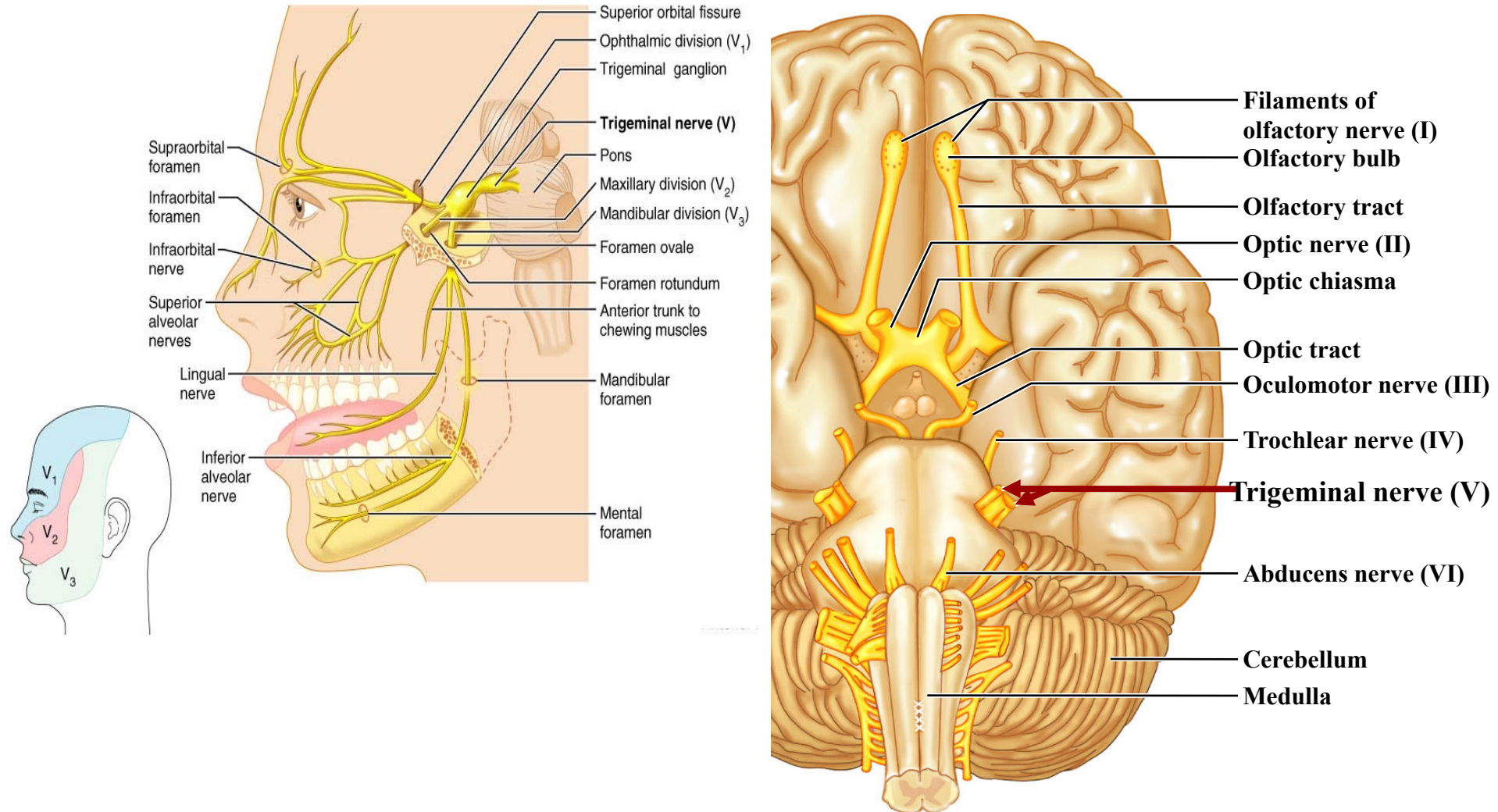
Trochlear Nerve (IV)

- Innervates the **superior oblique muscle** (an extrinsic eye muscle)



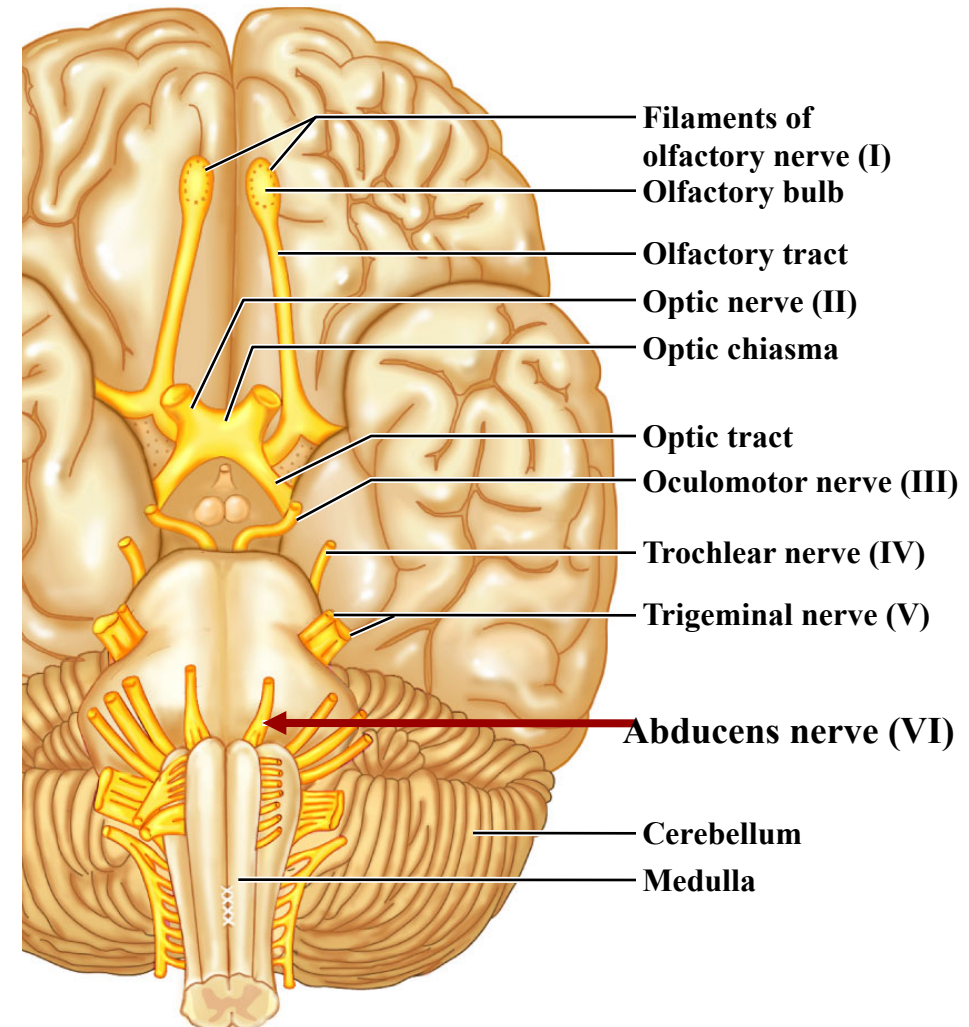
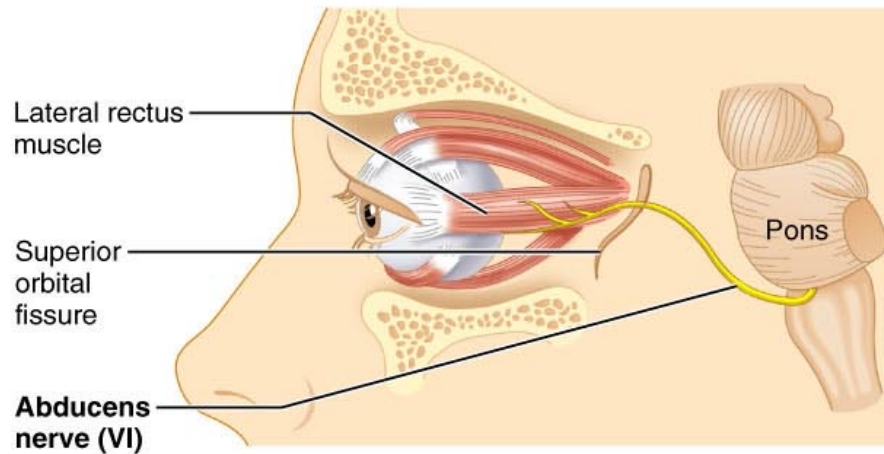
Trigeminal Nerve (V)

- Provides *sensory innervation* to the face
- Motor innervation to *chewing muscles*



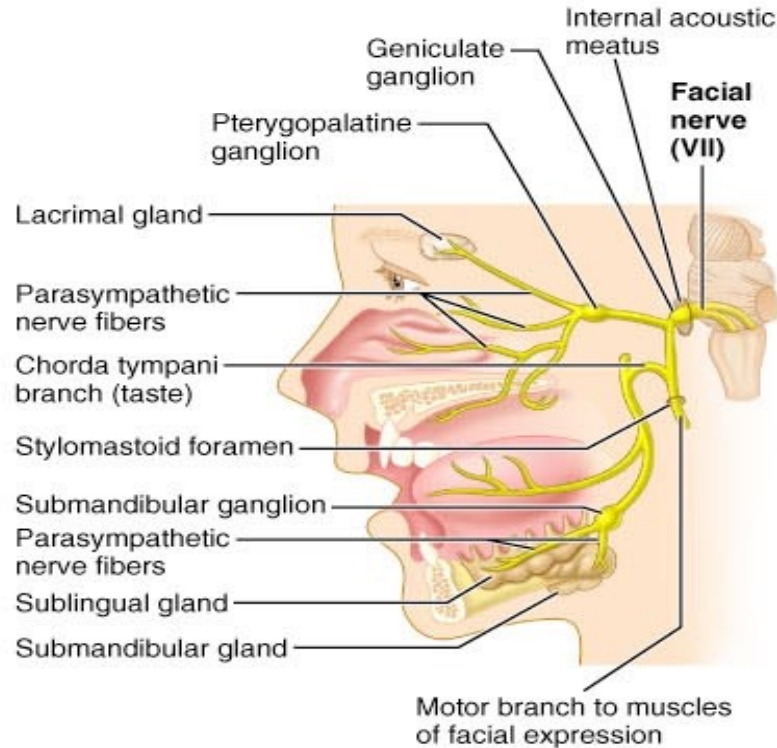
Abducens Nerve (VI)

- Abducts the eyeball – innervates lateral rectus muscle

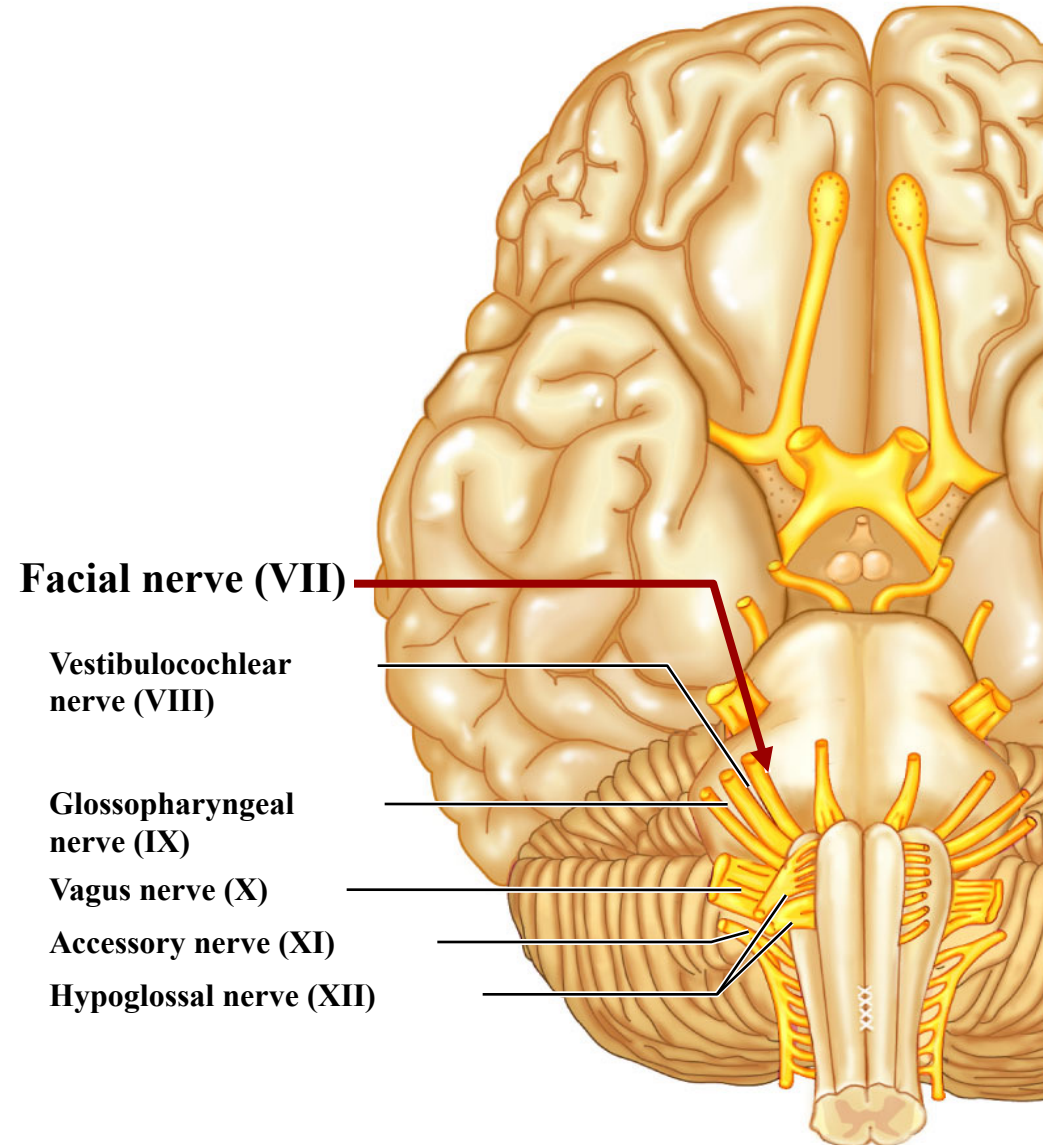


Facial Nerve (VII)

- Innervates muscles of facial expression

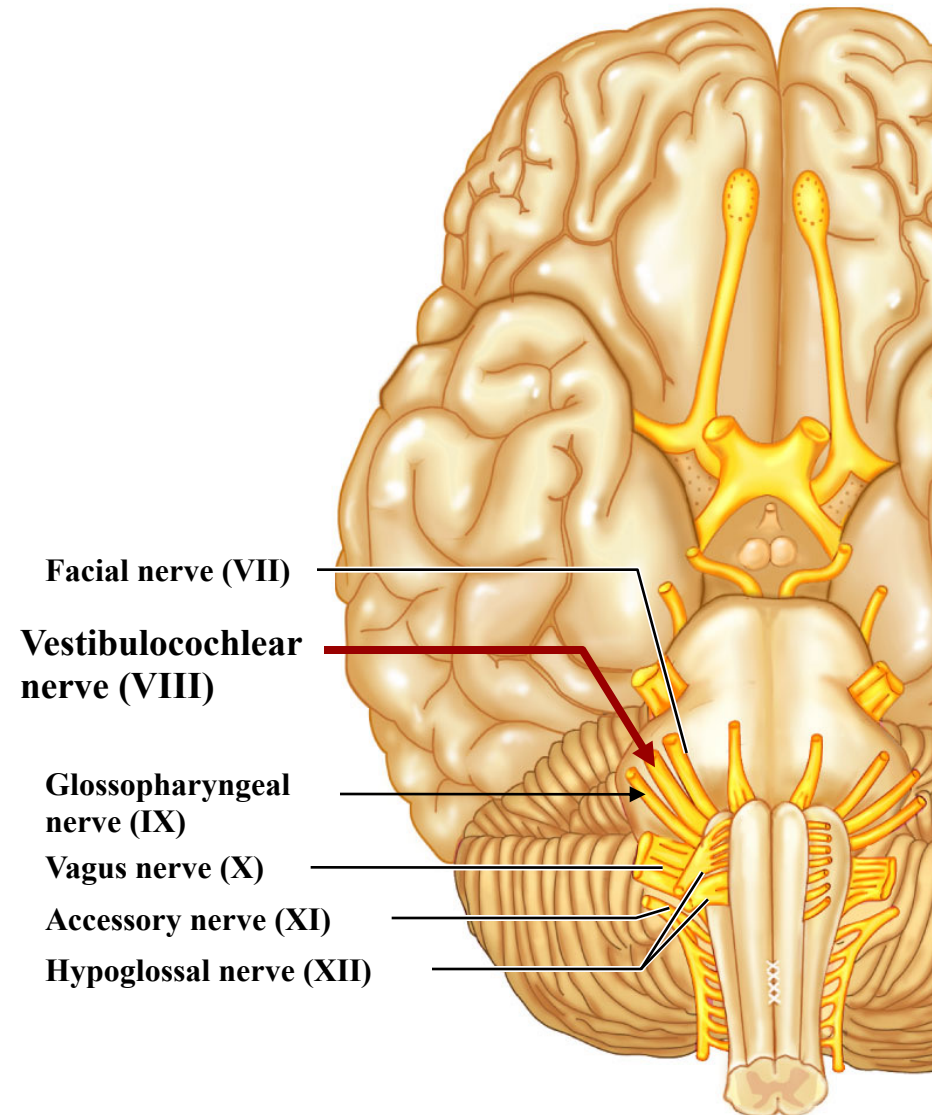
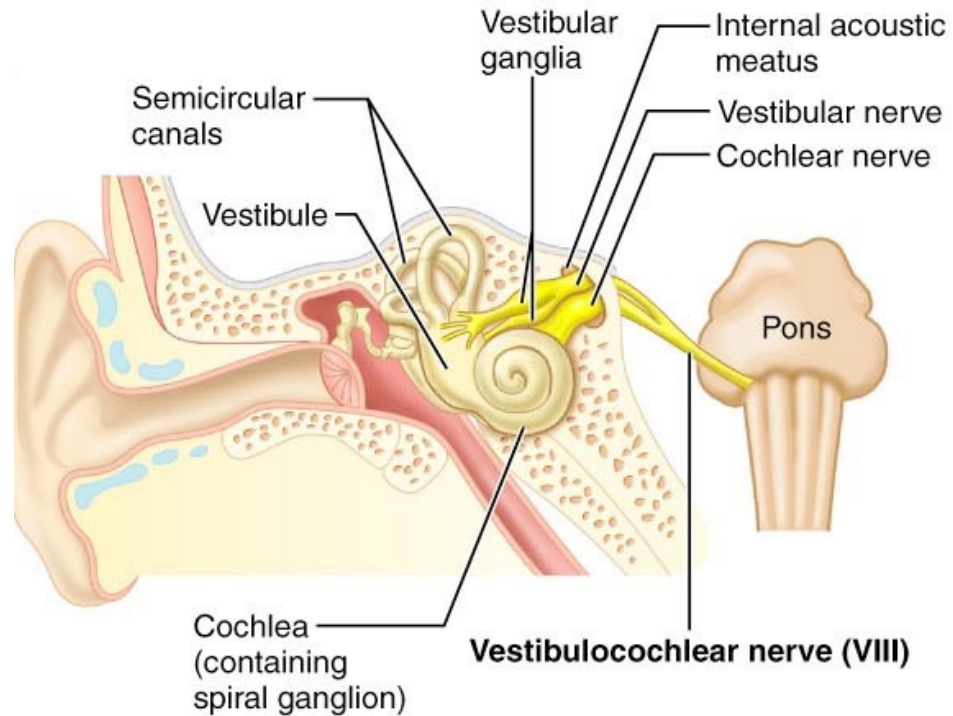


(c) Parasympathetic efferents and sensory afferents



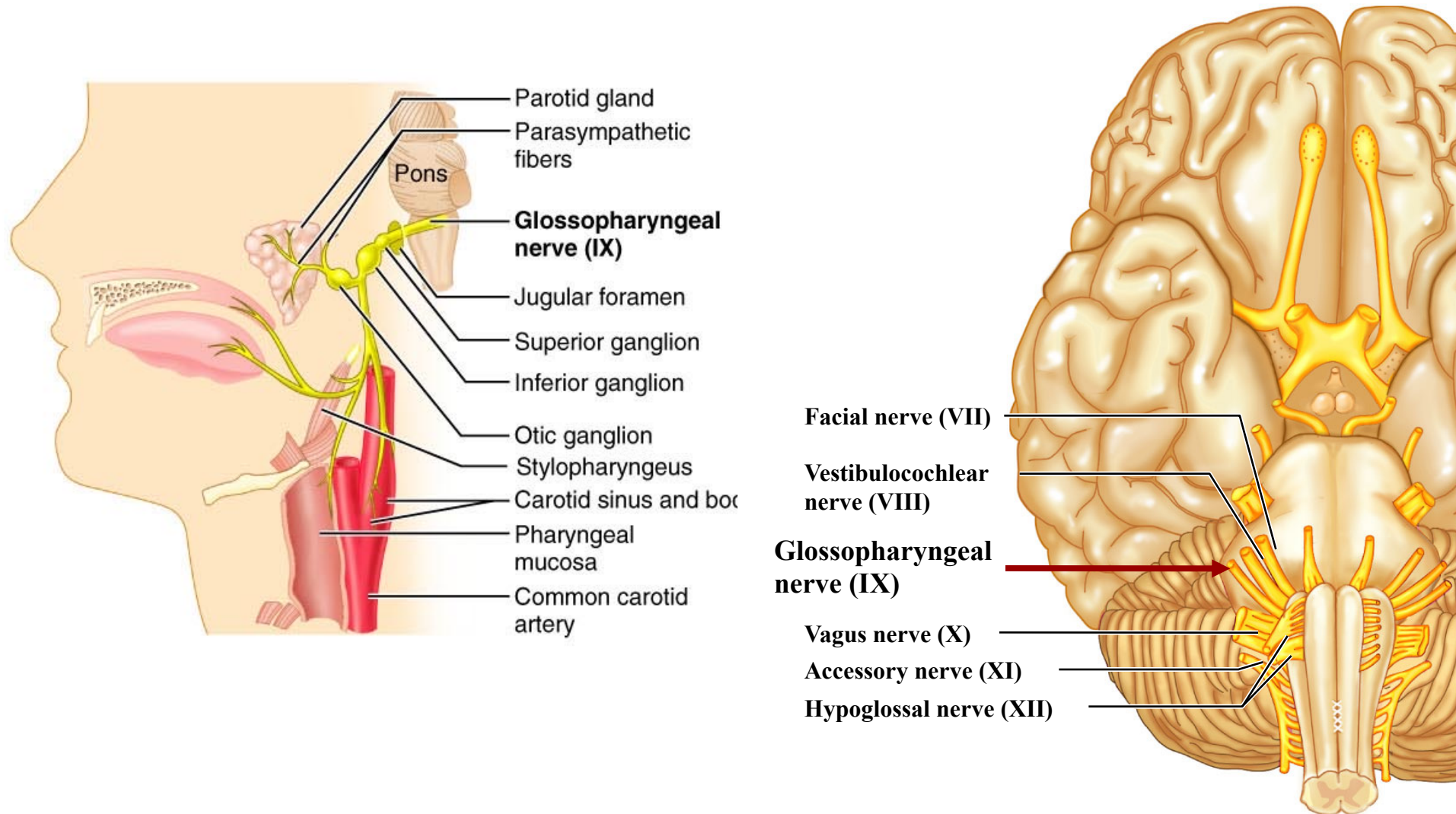
Vestibulocochlear Nerve (VIII)

- Sensory nerve of hearing and balance



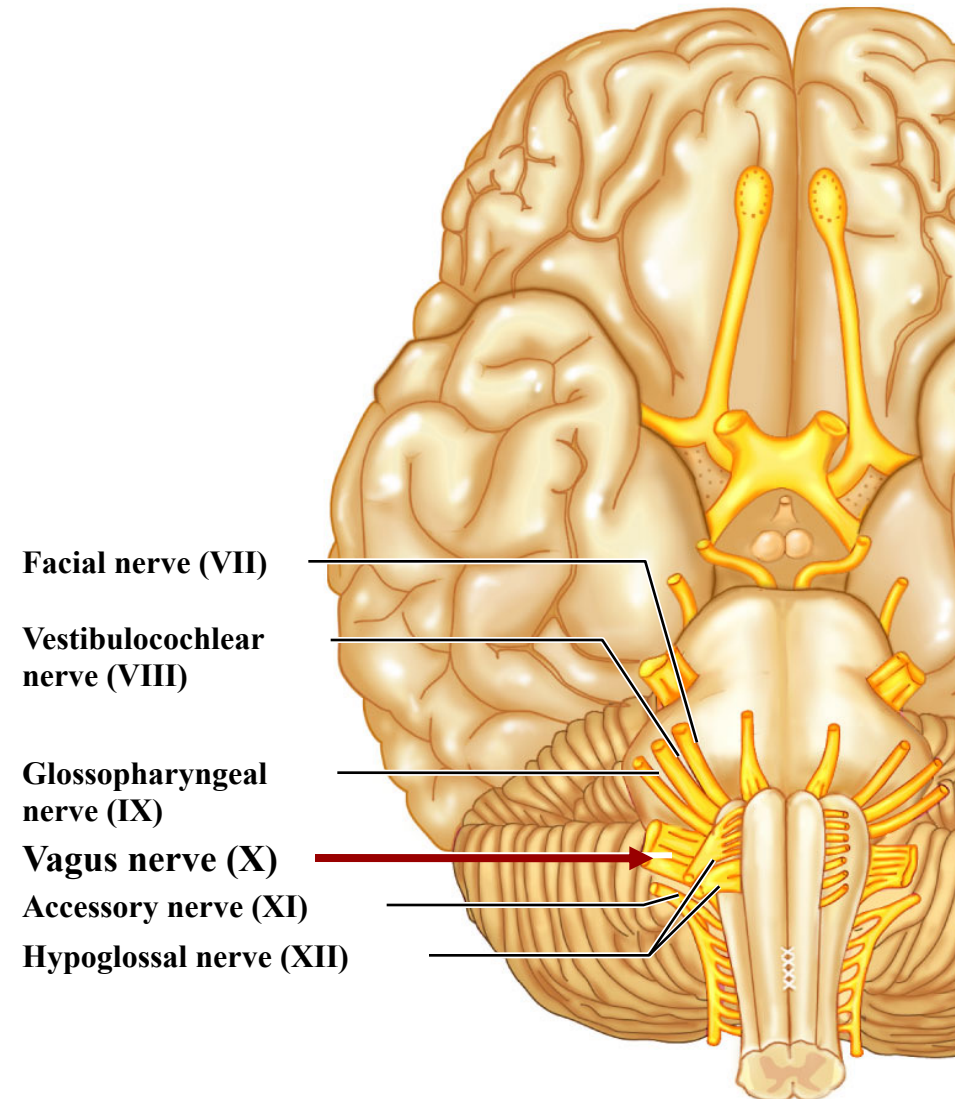
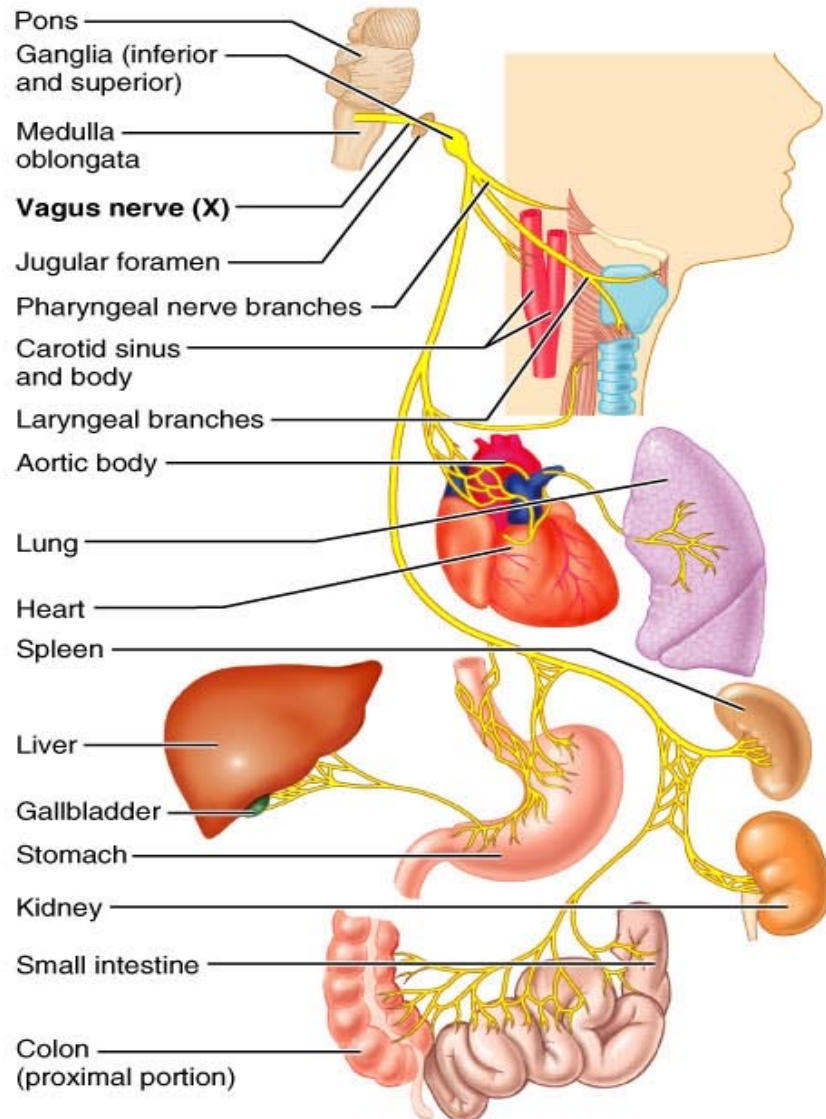
Glossopharyngeal Nerve (IX)

- Innervates structures of the tongue and pharynx



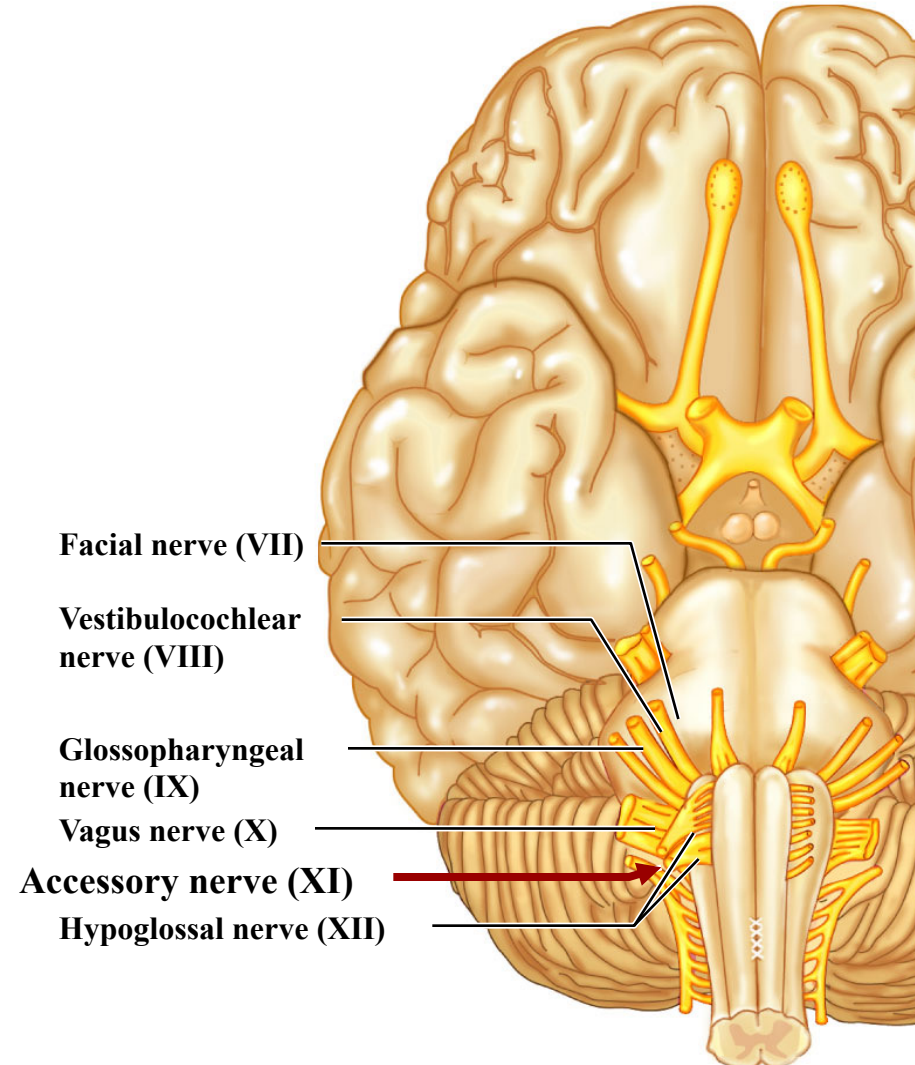
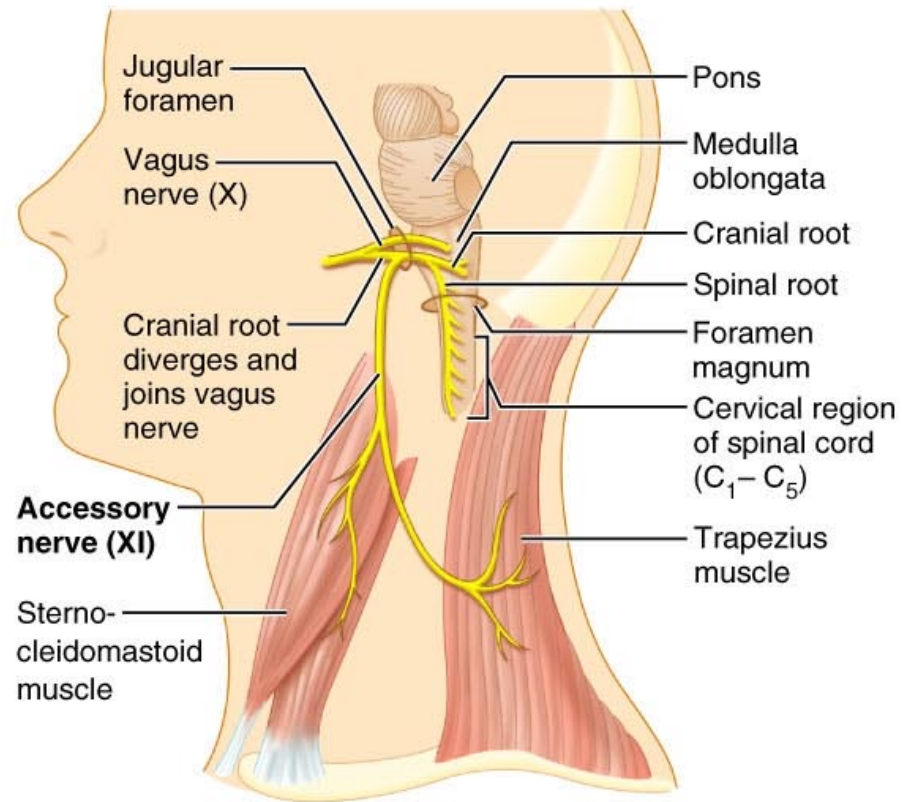
Vagus Nerve (X)

- A mixed sensory and motor nerve - “Wanders” into thorax and abdomen



Accessory Nerve (XI)

- An accessory part of the vagus nerve -innervates trapezius muscle



Hypoglossal Nerve (XII)

- Runs inferior to the tongue - innervates the tongue muscles

